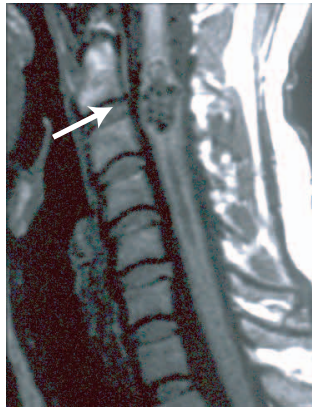
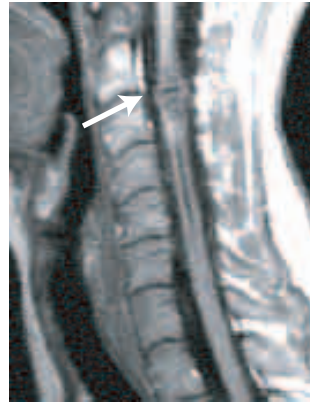

Extracranial Treatment of a C2-C3 Level Intramedullary AVM



Courtesy of T. Guerrero, MD, Stanford University, Stanford CA USA

BEFORE TREATMENT



4 YEAR FOLLOW-UP

Patient History

A 41-year-old female with C2-C3 spinal cord AVM who suffered 3 prior hemorrhages over a 15 year span and went on to develop disabling and progressive spastic quadriparesis with Brown-Sequard syndrome and significant loss of right hand function. She underwent CyberKnife stereotactic radiosurgery, and at 1 year post-treatment the patient displayed improved cervical spinal cord function, including improvement in right hand function and gait. At 2 year post treatment, repeat MRI scans revealed the size of the AVM had significantly decreased with significant reduction in vascularity as determined by the size and number of flow voids. Angiogram at 3-years showed 70% obliteration of the AVM; however, there was still a small residual nidus and she underwent a second radiosurgery.

CyberKnife Advantage

It was felt that there was little chance that the residual nidus would be obliterated over the next year without further treatment and that the patient would be at continued risk for another hemorrhage. The patient was not a candidate for microsurgical resection or embolization due to the intramedullary nature of the AVM, and the CyberKnife could easily re-treat the nidus.

Treatment

In 1997, the patient was treated on the frameless CyberKnife System at Stanford University with a 10 mm. collimator using 3 fractions to a total peripheral dose of 21 Gy. Three years later, the patient was re-treated with a 7.5 mm. collimator to a prescribed dose of 15 Gy to the 85% isodose line in 2 fractions.

Outcome & Follow-Up

The patient tolerated the second course of radiosurgery extremely well and there were no complications. At 4 year anniversary, the MRI scan shows continued improvement and the patient doing very well.

CyberKnife Team



Radiation Oncologist:

Steven Hancock, M.D.

Neurosurgeons:

John Adler, M.D.

David P. Martin, M.D.

Physicists:

Paul Geis, Ph.D.

Jenny Hai, Ph.D.

Martin Murphy, Ph.D.

Radiation Therapist:

Nalani Brown, RTT