

PROSTATIC ADENOCARCINOMA

San Diego CyberKnife Center Team:

Radiation Oncologist: Donald B. Fuller, M.D.

Medical Physicist: Chad Lee, Ph.D.

CyberKnife Center:

San Diego CyberKnife Center

San Diego, California



SAN DIEGO
CYBERKNIFE CENTER, inc.

PROSTATIC ADENOCARCINOMA

DEMOGRAPHICS:

Sex: M
Age: 76
History: Healthy, asymptomatic retired executive, presented with PSA 7.7 ng/ml - Jan 2006, 9.4ng/ml – June 2006
Treat Date(s): July 2006

CLINICAL HISTORY:

Diagnosis: Prostate biopsy April 2006 (+)
 Gleason Score 3+3=6
 Adenocarcinoma involving 30% of tissue submitted
 Stage T2a (palpable nodule R base)
 Bone Scan, CT abdomen/pelvis - May 2006
 No evidence of metastatic disease

Case History:

The patient presented during a routine health appraisal evaluation with a PSA of 7.7 ng/ml dated January 2006. A prostate biopsy was conducted April 2006, revealing Gleason Score 3+3=6 adenocarcinoma involving 30% of the submitted tissue (the cancer location within the prostate was not further specified). A bone scan and CT of the abdomen/pelvis May 2006 showed no evidence of metastatic disease. His repeat PSA level in June 2006 measured 9.4 ng/ml.

During his initial radiation oncology evaluation he was found to have an International Prostate Symptom Score (IPSS) of 4 and Sexual Health Inventory (SHI) score of 23; Stage T2a lesion at the right base. The patient signed the IRB-approved consent form for the Virtual HDRsm CyberKnife Radiosurgery Monotherapy Protocol.

CyberKnife Treatment Rationale:

The Virtual HDRsm CyberKnife Monotherapy Protocol was initially developed by principal radiation oncology investigator, Donald B. Fuller, M.D., of the San Diego CyberKnife Center. This protocol is IRB approved, and began enrolling patients in July 2006.

Working Concept:

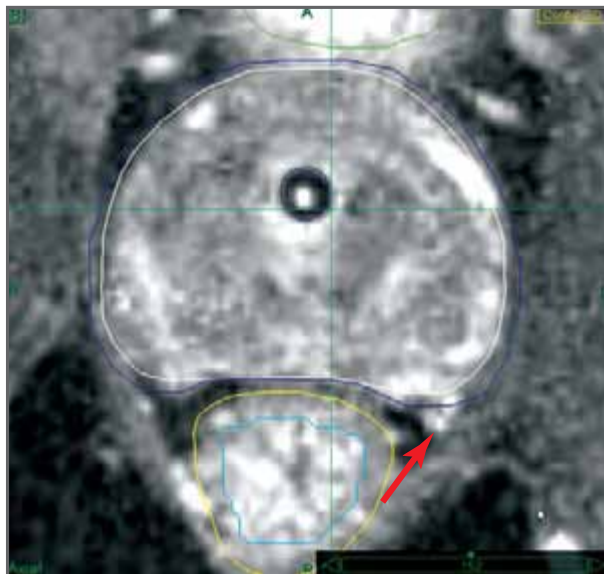
- We model our CyberKnife (CK) approach after High Dose Rate (HDR) brachytherapy, using peer reviewed HDR dose fractionation and comparable dose molding
- CK represents a non-invasive HDR delivery tool

Endpoints:

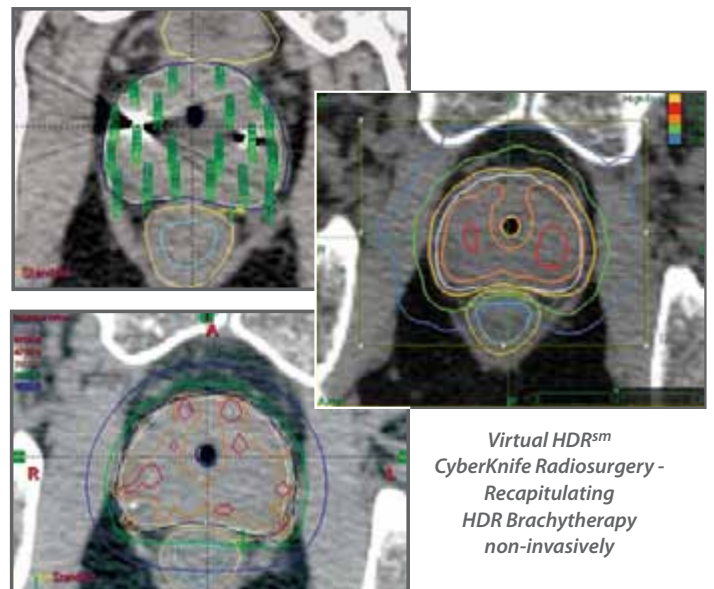
Primary: Detailed Baseline and follow-up QOL analysis

Secondary: PSA-based DFS

Tertiary: Compare CyberKnife vs. HDR brachytherapy dosimetry directly



T1-weighted, gadolinium-enhanced, treatment planning image; Prostate defined by white line; Planning Target Volume (PTV) defined by blue line; Rectal wall and Rectal mucosa defined by yellow and turquoise lines, respectively. NVB Visible (red arrow)



HDR Prostate Brachytherapy – Effective radiation dose sculpting but 17 transperineal catheters required for delivery

Virtual HDRsm CyberKnife Radiosurgery - Recapitulating HDR Brachytherapy non-invasively

PROSTATIC ADENOCARCINOMA

TREATMENT DETAILS:

Tumor Volume:	55cc	Path Template:	Single collimator long path
Imaging Techniques:	CT, MRI	Tracking Method:	6D fiducial tracking
Rx Dose & Isodose:	38 Gy to 57%	Collimator(s):	1.5 cm
Conformality Index:	1.10	Number of Beams:	261

Planning Process and Goals:

Two Image Sets:

- "A" series = 16 detector CT; 1.5 mm slices
- "B" series = T1 fat sat MRI (1.5T) with Gadolinium; 2 mm slices to better define prostate capsule, rectal mucosa, NVB structure and penile bulb

A foley catheter was used to image the urethra for both image sets and there was 100cc H₂O in the bladder for both image sets. This was also done with an empty rectum (Fleets).

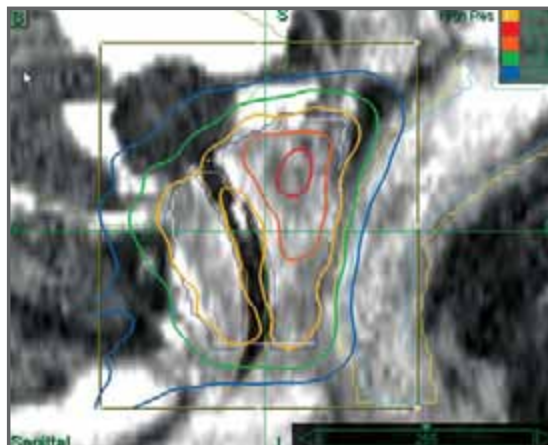
Dosimetry

- Rx 57% isodose line; New Conformality Index - 1.10
- PTV: V100 – 96.4%, V150 – 10.4%, D90 – 39.6Gy
- Urethra: Dmax – 44Gy (116%); Median – 38.4Gy (101%)
- Rectum Outer Wall: Dmax – 34.7Gy (91%)
- Rectum Mucosa: Dmax - 25.3Gy (67%)
- NVB: Steep gradient: 48Gy (126%) - 26.8Gy (71%)
- Penile Bulb: Dmax – 22.7Gy (60%); D50 – 7.3Gy (19%)

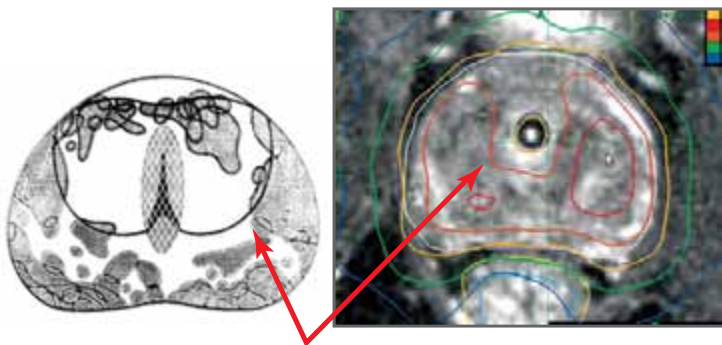
Treatment Delivery

Four transperineal prostate fiducials were placed and CT/MRI co-registered treatment planning - July 2006.

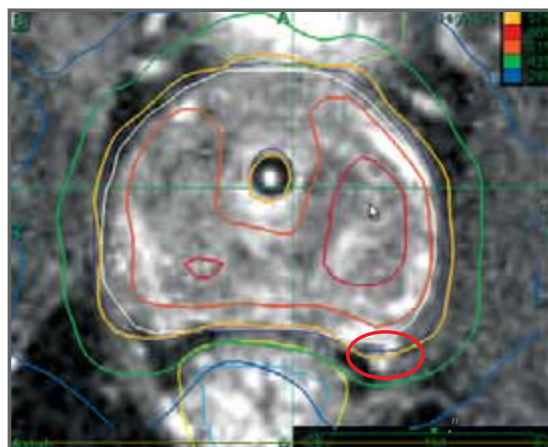
The patient was treated with 3800 cGy in four fractions - July 2006.



Sparing urethra and creating a very sharp dose gradient over the rectum – Prescription dose line is light orange



Highest dose is concentrated to match peripheral zone cancer cell distribution.¹ Prescription dose line (light orange) wraps tightly around the entire prostate, while hyper-dose regions (found within the "horseshoe-shaped" darker orange line inside the prostate) correspond with the peripheral zone of the prostate, which typically harbors the vast majority of a patient's prostate cancer cells.



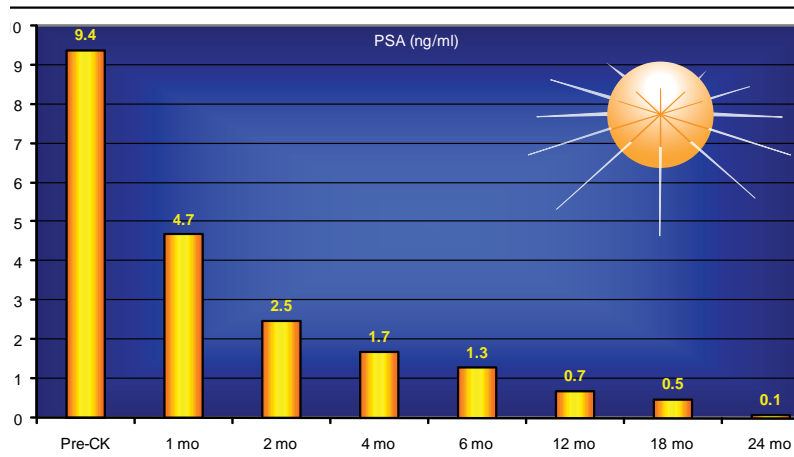
NVB is partially spared from the full dose zone

PROSTATIC ADENOCARCINOMA

Outcome and Follow-up:

Morbidity for this case:

- **Pre-CK:** IPSS 4; BM normal; SHI 23; No Flomax
- **2 week:** IPSS 14; (+) dysuria; On Flomax; Increased BM frequency;
- **1 month:** IPSS 10; (-) dysuria; On Flomax; BM better but "not normal"
- **2 month:** IPSS 3; Off Flomax; BM normal; SHI 22
- **4 month:** IPSS 5; Back on Flomax (Improved urinary flow with it); BM normal; SHI 16



PSA response

Conclusion and CyberKnife Advantage:

CyberKnife radiosurgery was selected by this patient because of its precision, and he also appreciated the compressed time course of treatment delivery compared with conventional radiotherapy. Our approach has been designed to mimic HDR brachytherapy dosimetry, as HDR brachytherapy naturally escalates the dose to the peripheral zone of the prostate, which typically harbors the majority of cancer cells.¹ HDR brachytherapy also has compelling literature demonstration of efficacy and safety.² Based on the unique radiobiology of prostate cancer, which is particularly sensitive to large dose per fraction (hypofractionated) radiation treatment, there is solid biologic rationale for treating prostate cancer patients in this manner.³ Clinical experience remains limited, but there are emerging data indicating a favorable PSA-response to CyberKnife prostate radiosurgery, with a median 18-month PSA result of 0.22 ng/ml.⁴ Our own study demonstrates a consistent, significant early biochemical response, with the above illustrated PSA graph being typical of our experience to date.⁵ Treatment related toxicity to date has included grade I - II urinary symptoms that normally resolve in 4 - 6 weeks, and grade 0 - I rectal symptoms that normally resolve in 2 - 3 weeks.

CYBERKNIFE AT SAN DIEGO CYBERKNIFE CENTER (www.sdcyberknife.com)

San Diego CyberKnife Center, the first CyberKnife facility in San Diego, was installed in June 2006. The CyberKnife is an image-guided robotic radiosurgery system, allowing physicians to provide a targeted, accurate and painless alternative to open surgery. In the case of prostate cancer, it appears capable of effectively delivering a powerful, short course of high-precision radiation, which is convenient and well tolerated by the patient. It has also been extensively used in CNS, lung, pancreatic and liver radiosurgical applications.

The San Diego CyberKnife Center was developed in partnership between Radiation Medical Group, Western Cancer Center and other local medical and surgical specialists. We strive to deliver clinical excellence and compassionate care.

References:

1. McNeal JE, Redwine EA, Freiha FS, Stamey TA. Zonal distribution of prostatic adenocarcinoma: Correlation with histologic pattern and direction of spread. *Am. J. Surg. Pathol.*, 1988; 12:897-906 MEDLINE
2. Grills IS, Martinez AA, Hollander M, Huang R, Goldman K, Chen PY, Gustafson GS. High dose rate brachytherapy as prostate cancer monotherapy reduces toxicity compared to low dose rate palladium seeds. *J Urol.* 2004 Mar;171(3):1098-104.
3. King CR, Lehmann J, Adler JR, Hai J. CyberKnife radiotherapy for localized prostate cancer: rationale and technical feasibility. *Technol Cancer Res Treat.* 2003 Feb;2(1):25-30.
4. Hara W, Patel D, Pawlicki T, Cotrutz C, Presti J, King C. Hypofractionated Stereotactic Radiotherapy for Prostate Cancer: Early Results. *Int J Rad Oncol Biol Phys.* 2006 Nov;66(3-Suppl):S324-325
5. Fuller DB, Lee C, Hardy S, Jin H. Peripheral Zone Dose Escalated CyberKnife Prostate Radiosurgery: Dosimetry Comparison with HDR, 6th Annual CyberKnife® Users' Meeting. La Quinta, CA, 2007 Jan 26